



PRESENTING CLINICAL SIGNS

DATE History: Grade 1/6 murmur.

ECHOCARDIOGRAPHIC FINDINGS

5/4/23 2D, M-mode, and Doppler study.

PERFORMED BY: There is mild left atrial dilation. The mitral valve is normal. Left ventricular wall thickness is normal. Left ventricular internal dimensions are normal. Left ventricular systolic function is normal. The aorta and aortic valve are normal. Right atrial and right ventricular dimensions are normal. The tricuspid valve is normal. The pulmonary artery and pulmonic valve are normal. No shunting lesions are visualized. No pericardial effusion or cardiac masses are seen.

Kelly Vazquez

INTERPRETED BY

Keith Blass, DVM,
MS, DACVIM
(Cardiology)

LA/Ao - 1.52
IVSd - 5.1 mm
LVPWd - 4.9 mm
LVIDd - 14.7 mm
LVIDs - 6.8 mm
FS - 52.3%
LVOT - 0.83 m/s
RVOT - 0.90 m/s

PATIENT

Boris Pileggi

ASSESSMENT/RECOMMENDATIONS

SPECIES

Feline This examination demonstrates mild dilation of Boris's left atrium, with differentials for this finding including a restrictive cardiomyopathy (RCM), atrial myopathy, and cardiac thyrotoxicosis. Given the presence of mild left atrial dilation, Boris's risk for the development of congestive heart failure, thromboembolic disease, and/or arrhythmia formation is mildly increased, and careful monitoring for the development of clinical signs of cardiac dysfunction (ex. labored breathing, limb paralysis, collapse) is recommended going forward.

BREED

Persian

No reason for Boris's murmur is appreciated in the image set.

SEX

A T4 level is recommended.

MN

No therapy is recommended at this stage of Boris's cardiac disease.

AGE

A recheck echocardiogram is recommended in 6 months. Thoracic radiographs are recommended if Boris experiences respiratory clinical signs.

12 y

WEIGHT

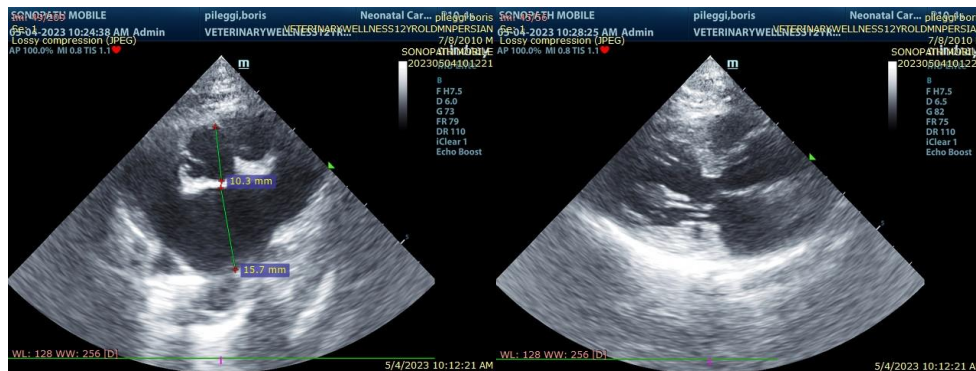
8.3 lb

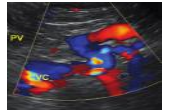
HOSPITAL NAME

Veterinary Wellness Center

REFERRING VET

Dr. Sepulveda





DATE The information and recommendations provided are based on the images presented by the referring veterinarian. No evaluation can be communicated regarding pathology that was not visible in the image/video clips provided.

5/4/23

Thank you for this referral. If the clinical or image interpretation does not parallel your findings or if I can be of any further assistance please contact me.

PERFORMED BY:

Kelly Vazquez

Keith Blass, DVM, MS, DACVIM (Cardiology)
KeithBlass@gmail.com
631-804-5754

INTERPRETED BY

Keith Blass, DVM,
MS, DACVIM
(Cardiology)

PATIENT

Boris Pileggi

SPECIES

Feline

BREED

Persian

SEX

MN

AGE

12 y

WEIGHT

8.3 lb

HOSPITAL NAME

Veterinary Wellness
Center

REFERRING VET

Dr. Sepulveda